



PATIENT PRESENTING CLINICAL SIGNS

Mickey Mercedes History: Elevated pancreatic values.

Physical Examination: N/A.

SPECIES

Urinalysis: N/A.

Canine

CBC: N/A.

BREED

Serum Biochemistry: PSL – 8922 u/L, amylase – 7040 u/L.

Silkly terrier

Radiographic Findings: N/A.

SEX

ULTRASONOGRAPHIC EXAMINATION OF THE ABDOMEN

MN

Urinary System

AGE

Full urinary bladder with a normal thickness and appearance of the wall. Normal anechoic urine with no sediment or uroliths evident.

4½ years

Normal trigone area, proximal urethra, and iliac blood vessels.

WEIGHT

Normal iliac lymph nodes. Ureters not visualized.

11.9 #

Left kidney – small (3.1 cm) with a mottled echogenic appearance, loss of cortico-medullary differentiation, pyelectasia, and an irregular capsule.

INTERPRETED BY

Right kidney – normal size (right 4.3 cm), echogenic appearance, cortico-medullary differentiation, pelvis, and capsule.

Remo Lobetti, BVSc,
MMedVet (Med), PhD, Dipl.
ECVIM

Reproductive System

IMAGING PERFORMED BY

N/A.

Dr Paul Kim

Adrenal Glands

HOSPITAL NAME

Normal shape, echogenic appearance, position, and size. Left 1.1 x 0.43 cm, right 1.64 x 0.5 cm.

Ridgefield Park Animal
Hospital

Spleen

REFERRING VET

Normal size and echogenic appearance. Smooth homogenous parenchyma, regular curvilinear capsule, and normal vasculature. No evidence of inflammatory, neoplastic, infarction, or infiltrative changes evident.

Dr Paul Kim

Liver

INVOICE

Normal size, echogenic appearance, portal markings, and regular curvilinear capsule. No nodules or masses evident. Full gall bladder containing moderate amount of hyperechogenic sediment. Normal thickness and appearance of the gall bladder wall. Normal bile duct.

304004

DATE

Gastrointestinal

1/10/23

Normal appearance of the stomach, duodenum, small intestine, ileo-cecal junction, and colon with no loss of layering, normal wall thickness, and no distension of the lumen.



PATIENT *Pancreas*

Mickey Mercedes Enlarged (left 0.4 cm, right 1.21 cm) with a mottled hyperechogenic appearance and irregular capsule. Hyperechogenic appearance of the mesentery and fat surrounding the pancreas.

SPECIES *Free Abdomen*

Canine No mesenteric lymphadenomegaly.
No ascites.

BREED

Silkly terrier

ULTRASONOGRAPHIC FINDINGS

Primary Findings:

- SEX**
 - Pancreatitis.
 - Left renal disease.
- MN

AGE

4½ years

Secondary Findings:

- Gall bladder sediment.

WEIGHT

11.9 #

INTERPRETATION OF THE FINDINGS & FURTHER RECOMMENDATIONS

The appearance of the pancreas is consistent with pancreatitis and in line with the elevated PSL assay.

INTERPRETED BY

Etiologies for the left kidney would be previous bacterial nephritis or acute kidney injury and a development anomaly.

Remo Lobetti, BVSc,
MMedVet (Med), PhD, Dipl.
ECVIM

Management of the pancreatitis would be fluid therapy, correction of electrolyte anomalies (as needed), anti-emetics, opioid analgesics, and low-fat intestinal diet. Short course of prednisolone (½ mg/kg SID for 3-5 days) can be considered as it has been shown to improve the recovery period in dogs with pancreatitis.

IMAGING PERFORMED BY

Dr Paul Kim

Although the gall bladder sediment may merely be an incidental finding and secondary to the pancreatitis, therapy with ursodiol and monitoring for the development of a mucocele would be recommended.

HOSPITAL NAME

Ridgefield Park Animal
Hospital

REFERRING VET

Dr Paul Kim

INVOICE

304004

DATE

1/10/23



PATIENT IMAGES

Mickey Mercedes **Pancreas**

SPECIES

Canine

BREED

Silkly terrier

SEX

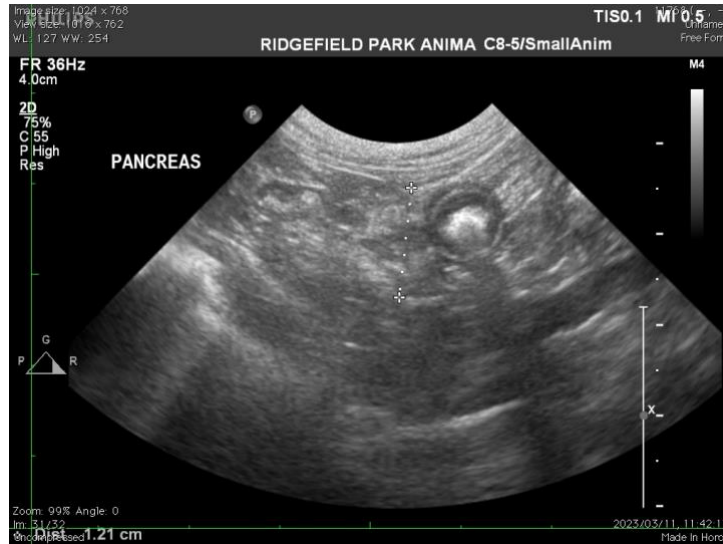MN

AGE

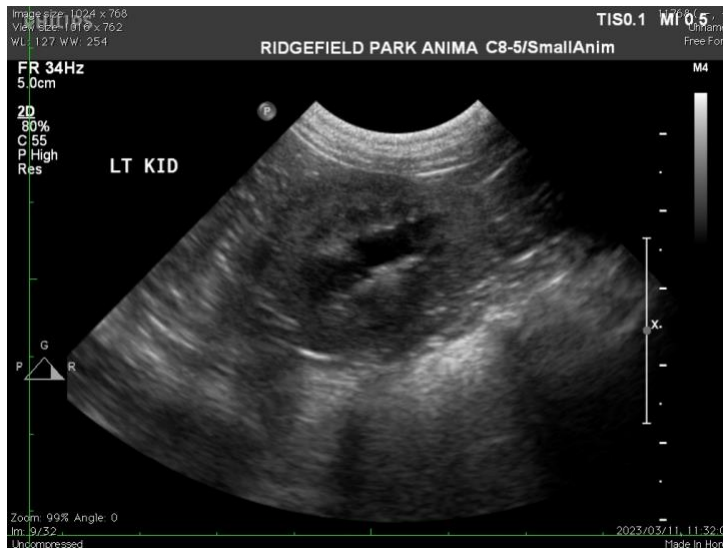4½ years

WEIGHT

11.9 #



Left kidney



INTERPRETED BY

Remo Lobetti, BVSc,
MMedVet (Med), PhD, Dipl.
ECVIM

IMAGING PERFORMED BY

Dr Paul Kim

HOSPITAL NAME

Ridgefield Park Animal
Hospital

REFERRING VET

Dr Paul Kim

INVOICE

304004

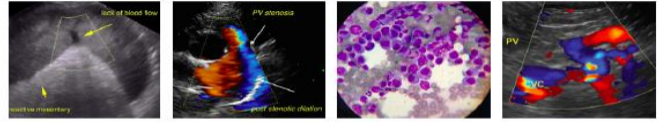
DATE

1/10/23

The information and recommendations provided are based on the images presented by the referring veterinarian. No evaluation can be communicated regarding pathology that was not visible in the image/video clips provided.

Thank you for this referral. If the clinical or image interpretation does not parallel your findings or if I can be of any further assistance, please contact me.

Remo Lobetti, BVSc, MMedVet (Med), PhD, Dipl. ECVIM (Internal Medicine)
remo.lobetti@sonopath.com



PATIENT rlobetti@mweb.co.za

Mickey Mercedes

SPECIES

Canine

BREED

Silkly terrier

SEX

MN

AGE

4½ years

WEIGHT

11.9 #

INTERPRETED BY

Remo Lobetti, BVSc,
MMedVet (Med), PhD, Dipl.
ECVIM

IMAGING PERFORMED BY

Dr Paul Kim

HOSPITAL NAME

Ridgefield Park Animal
Hospital

REFERRING VET

Dr Paul Kim

INVOICE

304004

DATE

1/10/23